

# **2D Pattern matching of frontal plane radiograph to 3D model identifies structural and functional deficiencies of the spinal pelvic system in consideration of mechanical spine pain and treatment options©**

**(AKA Spine distortion and mechanical spine pain)**

Raymond Wiegand, D.C.  
Spine Rehabilitation Institute of  
Missouri [Hcpc02@hotmail.com](mailto:Hcpc02@hotmail.com)

## **INTRODUCTION AND BACKGROUND**

Worldwide, back pain is the single leading cause of disability, preventing many people from engaging in work as well as other everyday activities. Back pain affects nearly 80% of the population at some point and is the most common cause for missed work (1). Most cases of back pain are mechanical or non-organic—meaning they are not caused by serious conditions, such as inflammatory arthritis, infection, fracture or cancer (2). However, there is no single procedure to identify the mechanical components related to spine pain. This study reports on the development and application of a computer aided drafting (CAD) program that identifies structural and functional deficits of the spinal pelvic system from two dimensional radiographs.

When injury to the spinal system disturbs balance or visual orientation, the righting reflex activates a compensatory response using muscle contraction and mass displacement. This mechanical displacement process proceeds along the pathway of the coupled motions of gait including pelvic and spine rotation. The gait cycle is the motion pathway of the body and the gait cycle is the primary pathway of mechanical compensation. As a result of injury, the spine adapts into a compensatory non-neutral position of gait with all its associated coupled motions. This compensatory, non-neutral position of gait becomes inherent to the spinal system and is recorded on a patient's weight bearing x-rays. Therefore, a static biomechanical model of the spine and pelvis in a non-neutral position of gait is needed for patient comparison to assess structural integrity including mechanical and functional efficiency.

**PURPOSE:** The purpose of this procedure was to develop a 2D geometric model for patient comparison to identify structural and function deficiencies in consideration of mechanical spine pain and clinical intervention with manual medicine. To identify repeating distortion patterns and investigate their geometric properties and causes.

**SETTING:** Private office with data collection over 30 years. Database greater than 7,000 patients

**PROCEDURE:** The optimum spine resisting gravity was described in the frontal plane with the central vertical axis intersecting the center of C2 odontoid and the center of S1. The interlamina junction of each vertebra is located on the central vertical axis. In the sagittal pane the curvatures are regionally coherent with the endpoints of the curves located on the central vertical axis from posterior C2 at the pedicle-body junction to posterior superior S1. The geometric description is referred to a 3D minimum energy state (3D-MES) model as it satisfies the minimum energy constraints of a vertically loaded curved shaped object.

Frontal plane images of this 3D MES spine in non-neutral position of gait defined the geometric characteristics of the 2D MES model. The 2D MES model was used for patient comparison. The geometry of each motion segment was recorded by locating the four corners of the vertebra in the sagittal plane and the four corners of the vertebra and the interlamina junction in the frontal plane. Additional points were collected for sacrum, occiput and C1. A total of 225 points were collected representing the upright geometry of the spine in the frontal and sagittal planes. From these data points in excess of 300 linear, angular and radial measurements were calculated from a spinal CAD program. The CAD program provided for data collection, data management and patient comparison to the 2D MES model.

**Measuring AP Stress Lines** The viewing perspective is standing behind the patient

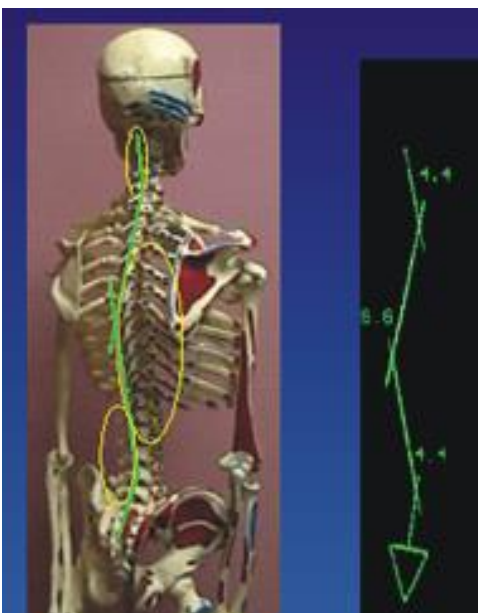
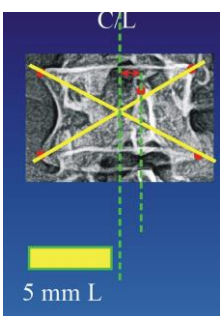


Figure 1 Projected AP Stress Lines

Figure 2

The AP stress Lines represent lateral bending in the frontal plane. The centers of the vertebra were calculated and connected at key locations representing the endpoints and apices of the sagittal curves. (Figure 1). The centers were calculated by intersecting lines drawn from the diagonal corners of the vertebra. The 3D MES spine produced predictable 2D AP stress lines due to partial projection of the sagittal curves into the frontal plane. (Figure 2). Collectively the stress lines demonstrate organization by sequential reciprocating convex curves in the lumbar, thoracic and cervical regions. Figures 4, 5 demonstrate the result of the sagittal curves projected into the frontal plane from right and left spine rotation.



**Measuring Vertebral Body Rotations (VBR)**

Vertebral body rotation (Figure 3) was determined by measuring the distance from the superior interlamina junction to the center of the vertebra. The result is illustrated as a proportional horizontal bar graph. Figure 9 illustrates a patient VBR and stress lines spinal map C2 through L5 with superimposition of the 2D MES model.

Figure 3

**RESULTS:** Figure 4 and figure 5 illustrate graphically the full geometric organization of the optimum 3D MES model when collapsed to a 2D image in the non-neutral positions of right and left spine rotation. The VBR of the 2D MES model are collectively illustrated C2-L5 and combined with the AP stress lines. Graphical illustration allows one to visually assess the co-dependent relationship of lateral bending and VBR for each spinal region.

Regionally the VBR demonstrated incremental increasing and decreasing amplitudes that were

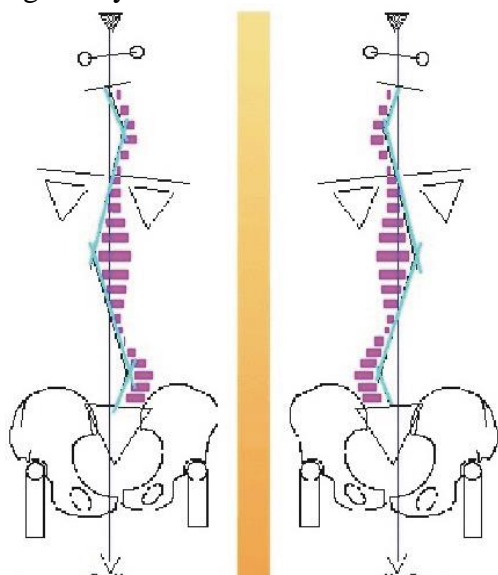


Figure 4  
Right spine rotation

Figure 5  
Left spine rotation

dependent on the vertebra location within the regional sagittal curves. These findings were due to offset placement of the spine to the central beam (3). There were reciprocating lateral bends in the lumbar, thoracic and cervical regions each proportional to the 3D MES model rotation and the amplitude of the sagittal plane curves.

The organizational geometry of figures 4 and 5 are classified as distortion Pattern 1. The geometry of Pattern 1 identified the segmental, regional and global organization of the optimum 3D model and the co-dependent relationship of the AP stress lines and the VBR. The geometric characteristics of figures 4 and 5 represent the highest level of anatomical, mechanical and functional organization of the spinal system. The findings are identified and classified as Pattern 1.

The organizational geometry of the 2D MES model will be used for patient comparison to identify abnormal lateral bending and VBR coupling.

### Biomechanical Findings of Organized Compensation

Left Compensatory Pattern Associated with Left Torso Rotation

- Left inferior sacrum
- Left ilium rotated posterior (PI)
- Resulting in functional left short leg
- Right ilium rotated anterior (AS)
- Left lumbar convex curve with left vertebral body rotations
- Right thoracic convex curve with left vertebral body rotations
- Left cervical convex curve with left vertebral body rotations .

**Physical findings** of left torso rotation and coupled compensation figure 6

Figure 6

**SAGITTAL CURVE FINDINGS** Anterior head translation (AHT) was found in greater than 99% of all patients disregarding the area of complaint. AHT activates the compensatory pathway as it creates an immediate unbalance torque at C7/T1. In response a helical shift occurs along the mechanical pathway of gait with the addition of lumbar and lower thoracic extension. This creates an equal and opposite torque at S1 creating a balanced moment arm. This compensation becomes inherent and exaggerates over time due to gravitational destabilization or repeated injury. Figure 7

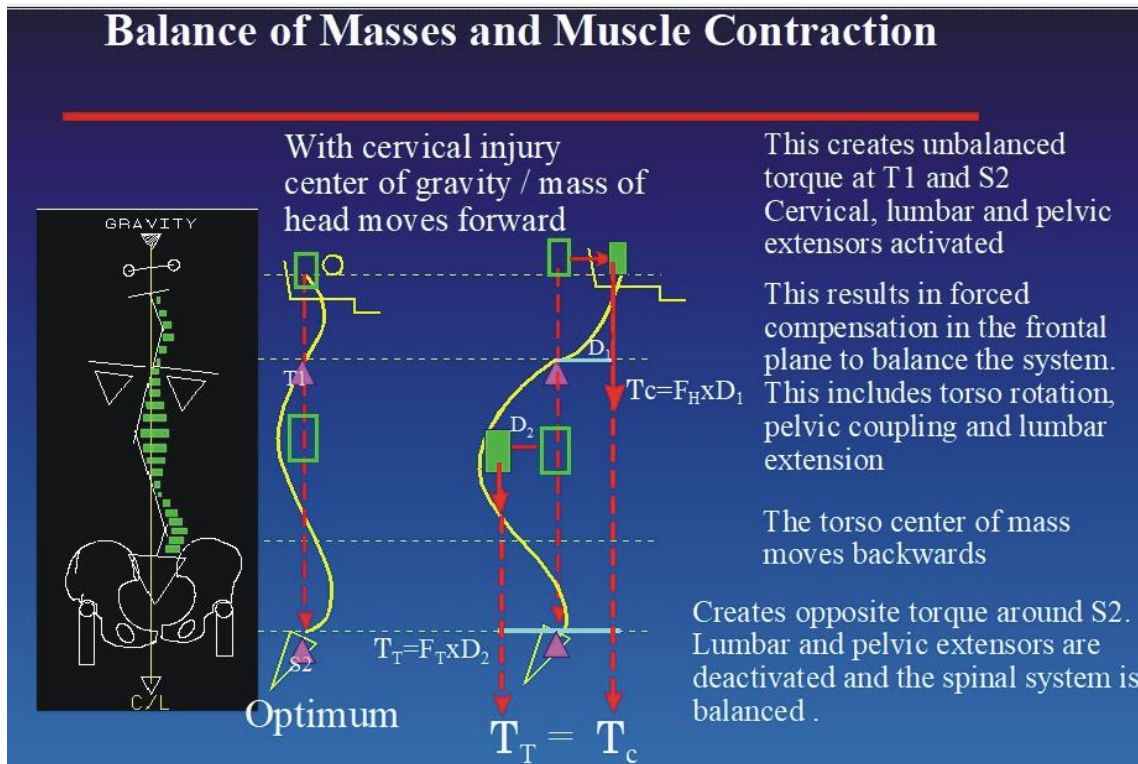


Figure 7

## DESTABILIZATION OF THE SAGITTAL CURVES

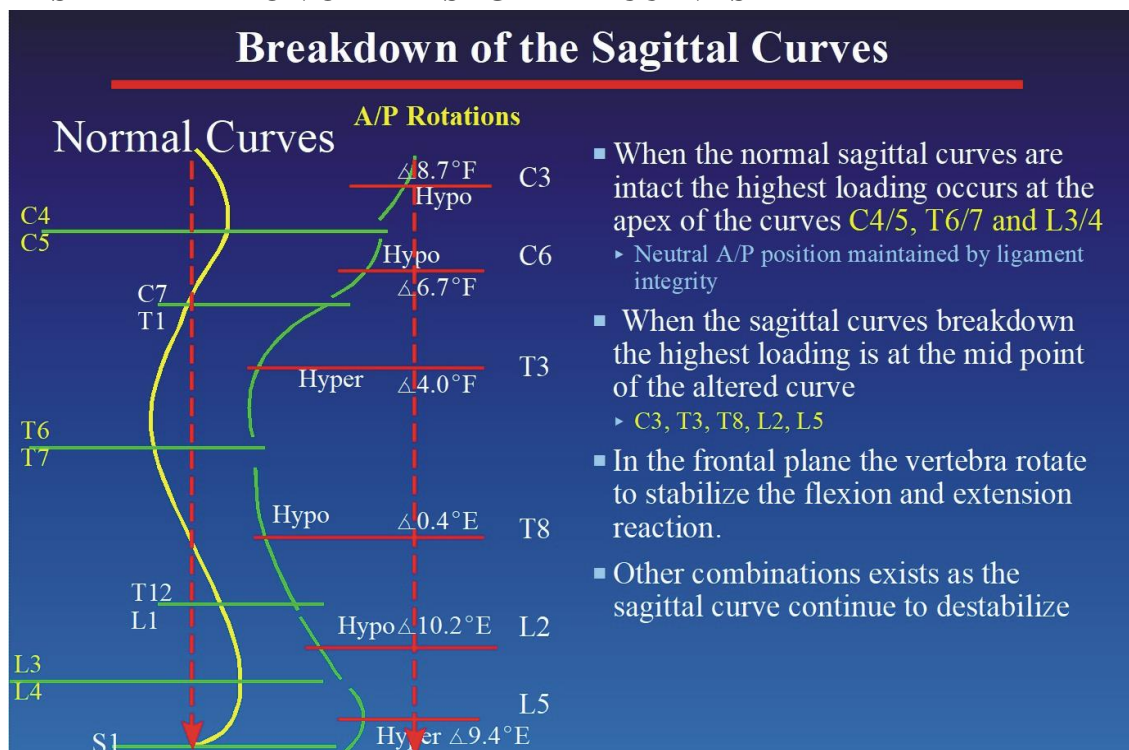


Figure 8

Destabilization of the sagittal curves occurs over time due to abnormal loading or injury. When the sample was examined, two dependent variables were identified. 1) the sagittal curves became non-coherent with distinct and different upper and lower radii of curvatures and 2) a shift in loading occurred from the normal apex vertebra to the apex vertebra of the non-coherent upper and lower regional curves. In the frontal plane the highest rotational differences (torsion) were recorded at these altered apex locations. Figure 8

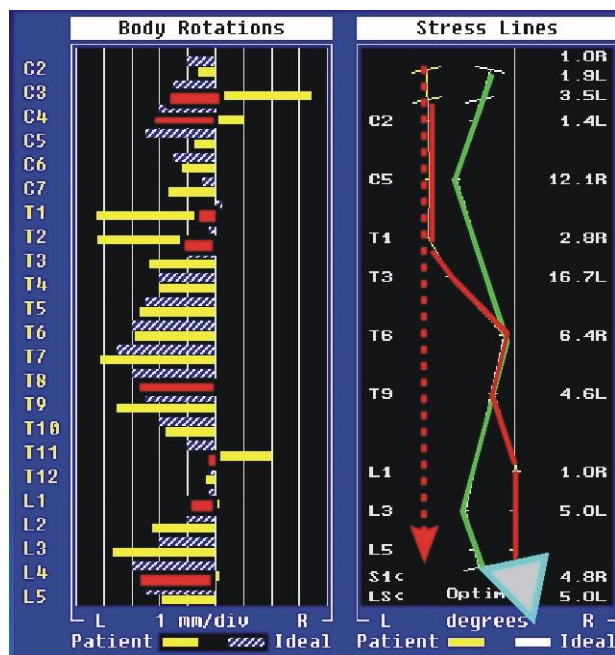
### CLINICAL FINDINGS: FRONTAL PLANE DISTORTION PATTERNS

From a sample of more than five thousand patients, six patient AP distortion patterns were identified in addition to Pattern 1 the 2D MES model.

The seven AP distortion patterns are as follows:

- Pattern 1 - Fully expressed 2D MES model with intact sagittal curves, VBR uncoupling
- Pattern 2 - reversed stress lines in the cervical region, disrupted cervical curve, compensated T, L
- Pattern 3 - reversed upper thoracic stress lines, disrupted sagittal curves, VBR uncoupling
- Pattern 4 - reversed mid thoracic stress lines, disrupted sagittal curves, VBR uncoupling
- Pattern 5 - reversed lower thoracic stress lines, disrupted sagittal curves, VBR uncoupling
- Pattern 6 - reversed lumbar stress lines, disrupted sagittal curves, VBR uncoupling
- Pattern 7 - multiple reversed stress lines, disrupted sagittal curves, VBR uncoupling

## PATIENT PATTERN MATCHING



The patient is matched to either a left or right 2D MES model. In this example figure 9, the patient (left window, yellow VBR) was matched to a left 2D MES model for VBR. There is abnormal VBR coupling (red bars left window) at C2, C3, T1, T2, T8, T11, L1 and L4 in comparison to the 2D MES model.

There is complete disorganization of the patient AP stress lines (right window, red solid) as compared to the 2D MES model (green).

Ligament injury and potential instability are present where the stress line geometry differs in comparison to the 2D MES model and or VBR uncoupling has occurred.

**Figure 9** Patient matched to a LEFT 2D MES Pattern 1 for VBR  
Patient destabilized to Pattern 7

## PATIENT EXAMPLE 73 YO female

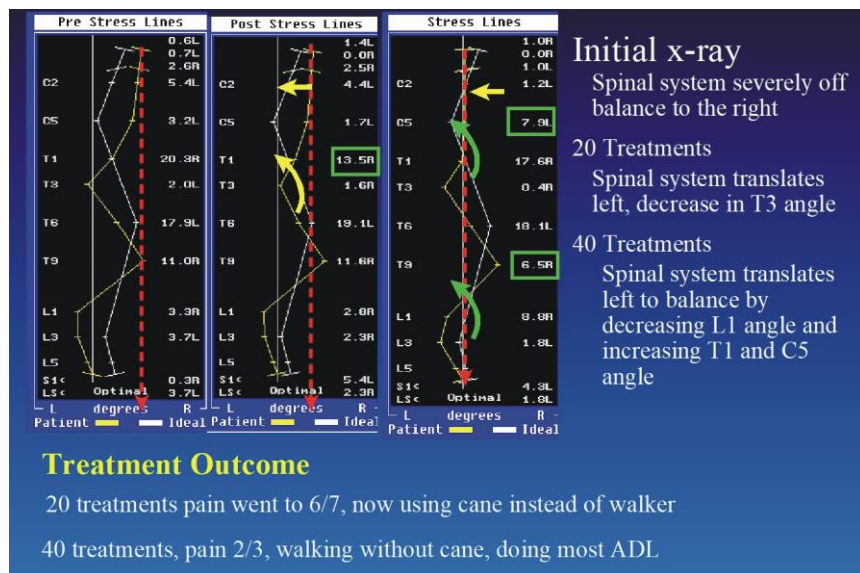


Figure 10 demonstrates the structural changes occurring as a result of clinical intervention.

History: Two years post lumbar fusions L3, L4, Anterior vertebral collapse L3 with reversed lumbar curve. degenerative scoliosis, 25 post-surgical injections. Pain rated at constant 8/9, confined to a walker, unable to perform any normal ADL. Told by surgeon to “learn to live with the pain”.

**Figure 10** Structural changes from clinical intervention

Diagnostic procedures included full spine radiographic examination in an upright weight bearing posture, structural and functional assessment with comparison to the 2D MES model. Clinical intervention based on the biomechanical assessment included physical medicine (spinal adjusting), traction and exercise rehabilitation. Treatment time less than four months.

## OVERALL CLINICAL OUTCOME

In a self-reporting study of 580 consecutive patients, patients reported initial pain on average as “SEVERE” Following ten treatments the majority of patients reported their pain as “MINIMUM”. Patients completed the following form every ten treatments.

Pain Level Beginning	Pain Level Present	Pain Level	Description of Pain and Dysfunction
		Absent	Pain is totally absent
	<b>X</b>	Minimal:	Present but forgotten with activity
		Mild:	Annoying but doesn't interfere with activity
		Moderate:	Pain requires modification of activity
<b>X</b>		Severe:	Unable to perform normal duties due to pain
		Very Severe:	Causes you to cry out in pain

**DISCUSSION** The spinal system is a multi-component, semi-rigid and elastic system. The system's structural integrity is dependent on the structural integrity of each motion segment. Movements of the spinal system are dictated by the singular and combined contributions of the segmental articulation, limited by the restraint of the ligaments with locomotion achieved by muscle action. The movements of the spine and pelvis act in harmony with coupled motions to achieve mechanical locomotion or gait (4). When injury or an anatomical deficiency disrupts the mechanical system, it adapts by compensating into a non-neutral position of gait. This includes the associated segmental, regional and global coupling. This torsional compensation shifts the relative position of concentrated body masses until static equilibrium is achieved by balance of torques and moment arms around S1. This non-neutral position of gait becomes inherent to the spinal system and is recorded on the frontal plane radiograph.

A 3D MES spine model was collapsed to a 2D frontal plane image at various non-neutral positions to simulate a non-neutral position of gait. The resulting 2D images identified the geometric organization of the 3D MES spine. The 2D geometry presented as a left and right pseudo-scoliosis resulting from partial projection of the sagittal curves into the frontal plane. The amplitude of regional lateral bending was predictable and proportional to the amount of spine rotation and the amplitude of the regional sagittal curve. On a segmental level the vertebral bodies of the 2D MES spine all rotated to the side of spine rotation with a predictable pattern of increasing and decreasing amplitudes. These patterns resulted from the vertebra's lateral offset to the central beam. When the spine is rotated to the central beam, the apex vertebra of the sagittal curves is displaced the furthest from the central beam and therefore demonstrates the highest amplitude of rotation. The projected lateral bending and VBR were predictive images based on central beam divergence and object placement. The 2D image of the 3D MES spine was classified as Pattern 1. A spine CAD program was used for data collection and management including patient comparison to the 2D MES model. From the data collection, six additional spine distortion patterns were identified in addition to Pattern 1, the 2D MES model. Each additional pattern represented abnormal regional lateral bending in comparison to the 2D MES model. Departure of the patient AP stress lines from the 2D MES model is indicative of ligament injury at that site as no altered image of the 3D MES spine is possible without disrupting normal physiology. When the patient is matched to either a left or right Pattern 1, mechanical and functional deficiencies can be identified for correction and rehabilitation.

When anterior head translation was recorded it was associated with derangement of the cervical, thoracic and lumbar sagittal curves. Due to abnormal loading these curves destabilized from single coherent curves into two distinct upper and lower curves with different radii of curvature with fixed flexion or extension. Sagittal curve disruption produced predictable motion segment uncoupling in the frontal plane. The most common vertebra with the highest level of uncoupling occurred at the apex vertebra of the altered upper and lower sagittal curves.

Segmental uncoupling produces aberrant joint loading and ligament loading resulting in diminished mechanical and functional efficiency. AHT has the opportunity to produce various pain syndromes including chronic neck, shoulder and inter-scapular pain. Low back and SI joint pain results from chronicity of the non-neutral position of gait including excessive lumbar extension. The patient is at risk for disc failure at L5/S1 as the body of L5 and S1 are chronically rotated in opposite directions due to the mechanical coupling during compensation. This aberrant position creates chronic internal shear forces within the disk. Abnormal position and loading results in long term degenerative pathology with potential implications for functional stenosis at the IVF and central canal. Separately and in combination these aforementioned disruptions to the mechanical system are potential contributors to the generation of mechanical spine pain.

**CONCLUSION** When the spinal system is injured or an anatomical deficiency exists the spinal system adapts mechanically into a non-neutral position of gait including the coupled pelvic motions, the coupled motion segment, including rotation and lateral bending and spine rotation. A comparative 2D MES model was developed by extracting the segmental, regional and global geometry from a 3D MES spine in a non-neutral position of gait. By matching and comparing the patient to the 2D MES model, mechanical and functional deficiencies were identified for treatment and rehabilitation. In addition to Pattern 1 the 2D MES model, six additional frontal plane distortion patterns were identified. More than 99% of patients, regardless of area of complaint presented with cervical curve disruption and anterior head translation. AHT disrupted the thoracic and lumbar curves. Each regional curve destabilized into two non-coherent curves leaning predictably forwards or backwards. Physical medicine and rehabilitation based on comparison to the 2D MES model proved successful as a majority of patients reported their pain reducing from SEVERE to MINIMUM in ten treatments or less. These findings demonstrate the usefulness of structural analysis by radiography to identify segmental, regional and global biomechanical deficits all of which contribute to mechanical spine pain at various local and distant locations.

## REFERENCES

1. Hoy, D, March L, Brooks P, et al. The global burden of low back pain: estimates from the Global Burden of Disease 2010 study *Annals of the Rheumatic Diseases*. Published first online 24 March 2014. DOI:10.1136/annrheumdis-2013-204428
2. Hartvigsen J et al. Low Back Pain Series: What Low Back Pain Is and Why We Need to Pay Attention. *Lancet*, June 2018; Volume 391, Issue 10137; p 2356-2367.
3. Carroll, Q. 1985. "Beam-Part-Film Alignment". *Principals of Radiographic exposure, processing and quality control*. 1985 3rd Ed. Charles C. Springfield, Illinois. Thomas Publishing.
4. Greenman, PE. Clinical aspects of walking. *Journal of Manual Medicine* (1990) 5:125-130.